

**German Shepard M. 8 Y old
Tricuspid dysplasia - Ebstein anomaly**

Dr. Caludio Bussadori, MD. DVM Dipl. ECVIM (Cardiology)
Clinica Veterinaria Gran Sasso, Milan, Italy

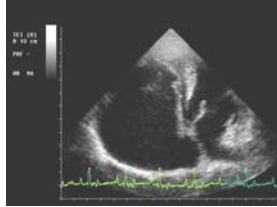


Fig 4150
Four Chamber apical view were we may observe right atrial dilatation, short tricuspid corde tendinee and lower displacement of the tricuspid in the right ventricle which result in a large portion of "atrialized" right ventricle.

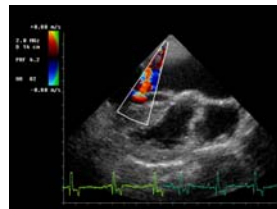


Fig. 4149
Right Parasternal short axis slightly rotate anticlockwise in order to the align the regurgitant flow with the ultrasound beam

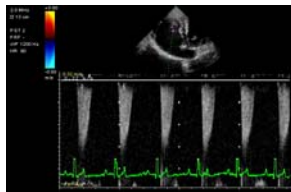


Fig 4148
CW Doppler of the. tricuspid regurgitation

Fox Terrier M. 1 Y old Pulmonic Stenosis

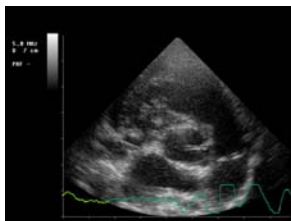


Fig. 4196
Right parasternal short axis, systolic frame with evidence of doming and leaflet fusion

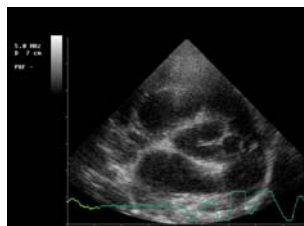


Fig.4194
Right parasternal short axis, diastolic frame with evidence of redundancy and fusion of the leaflets